

Original article:

A Clinicopathological study of tumors and tumor like lesions of oral cavity

¹Dr Manisha A Atram , ²Dr Vijay Bhalavi , ³Dr Sunita Dantkale

¹Assistant Professor , Department of Pathology , Mahatma Gandhi Institute of Medical Science , Sevagram, Wardha, Maharashtra

²Assistant Professor , Department of Biochemistry , Govt. Medical College, Nagpur , Maharashtra

³Professor , Department of Pathology , V. M. Govt. Medical College, Solapur , Maharashtra

Corresponding author: Dr Manisha A Atram, Department of Pathology, Mahatma Gandhi Institute of Medical Sciences, Sevagram, Wardha, Maharashtra

Abstract

Background: The oral cavity is one of the most common sites for various tumors and tumor like lesions. Among the malignant lesions, squamous cell carcinoma is single most common malignant lesion of this region.

Aims and Objectives: To study the histopathology of different tumor and tumor like lesion of oral cavity with relation to age, sex, site and risk factors involved in these lesions.

Material and Methods: This was a retrospective study carried out in the Department of Histopathology, V.M.G. Medical College, and Civil Hospital, Solapur. A total of 215 cases of oral cavity lesions were studied.

Results: Among 215 cases, 144 (69.97%) cases were malignant tumors, 18 (8.37%) were epithelial precursor lesions, 21 (9.76%) were benign tumors and 32 (14.88%) were tumor like lesions. The male to female ratio was 2.1:1. The most common site was the tongue (28.83%) in the present study. Majority of malignant tumor were Grade-I squamous cell carcinoma

Conclusion: A variety of benign and malignant tumors occur in oral cavity. However, the origin and nature of the oral cavity lesions cannot be confirmed by clinical examination alone. Hence, it is must to have a histopathological examination to confirm the histogenesis and malignant potential of the oral lesions.

Key words: Oral cavity, Benign, Malignant lesion

Introduction:

Oral cavity is an entrance to the digestive system and is directly exposed to tobacco, alcohol, and food.^[1] It is one of the most common sites for various tumours and tumour like lesions.^[2] Tumor may originate from epithelial tissue, connective tissue, muscle tissue, nerve tissue and from vessels.^[3]

In the developing world oral cancer is the third most common cancer after stomach and cervical cancer. An estimated 378,500 new cases of intra-oral cancer are diagnosed annually worldwide.^[4] The oral cavity is more accessible to complete examination; detection of

precancerous and cancerous lesions can be done at earlier stage. Oral cancer has better prognosis and may be controlled effectively, if it is diagnosed at an early stage.^[5] Biopsy of lesion of oral cavity is an easy O.P.D procedure and gives definitive diagnosis.

Material and Methods:

Retrospective study was carried out in the Department of Pathology, V.M Government Medical College, Civil Hospital, Solapur. A total of 215 (incisional biopsy, surgical specimen and reference slides) specimens were processed by routine paraffin method followed by

Hematoxylin and Eosin stain and reviewed by two pathologists.

Results:

Among 215 cases, 144 (69.97%) cases were malignant tumors, 18 (8.37%) were epithelial precursor lesions, 21(9.76%) were benign tumors and 32 (14.88%) were tumor like lesions, given in Table no 1. In the present study the affected age range was from 5 to 85 years with a mean age of 52 years. The peak incidence was in 5th decade. Table no. 2 shows age wise distribution. Lesions were more common in male (147 cases; 68.37%) than in females (68 cases; 26.38%). The male to female ratio was 2.1:1. The most common site was the tongue (28.83%) in the present study, given in Table no. 3. Majority of malignant tumor were Grade-I squamous cell carcinoma. In epithelial precursor lesions, Carcinoma in situ was noted in 6 patients and dysplasia in 12 patients. In benign tumor, haemangioma was the commonest lesion. Mucocele was the commonest tumor like lesion followed by pyogenic granuloma. .

Our study showed malignant lesions were more common than benign lesions which does not correlate with other authors researchers. This is because of the very small sample size as compared to the sample studied by other authors. Also biopsies sent to our department are mainly for the purpose of ruling out malignancy. So the percentage of malignancy is very much increased in our study.

Discussion:

The oral cavity is one of the most common sites for various tumours and tumour like lesions. Study includes a variety of 215 oral cavity lesions, both benign and malignant which were then analyzed for the purpose of studying the clinical aspects as well as histopathological patterns of oral lesions.

In 1971 WHO classified oral lesions into malignant tumors, benign tumor and tumor like lesion. Epithelial precursor lesions, variants of squamous cell carcinoma and other primary tumors of oral cavity were not included in this classification.^[6,7]

According to WHO 2005 classification, lesions of oral cavity are classified into malignant tumors and its variant, epithelial precursor lesions and benign tumor excluding tumor like lesion.^[8] In our study we have classified the oral cavity lesion considering both classification .Malignant tumors and epithelial precursor lesion are classified as per WHO 2005 classification. Benign tumor and tumor like lesions are classified according to 1971 WHO classification.

In our study, the affected age range was 05 to 85 years with mean age of 52 years. According to the studies done by N.N Khanna^[9] and S.P Khandelwar^[10], the peak incidence of oral lesion was seen in 6th decade . The incidence of oral cancer in young adults (3rd decade) was found to be increased (6.94%) in present study. This increase in incidence may be due to smokeless tobacco called Gutkha, which has targeted young people. Nowadays, gutkha has become extremely popular among youth.

In the present study the frequency of oral cancers in males and females was in a ratio of 2.1:1, showing male predominance. This is consistent with studies done by N.N Khanna^[9], P.K Varshney. ^[11] The exception to this is a study from Madras which showed female predominance due to social and cultural practice of 'Pan' chewing habits.^[12]

Oral cavity lesions can occurs at any site including lips, gums, buccal mucosa, tongue hard and soft palate. N.N Khanna^[9]. study show lip as the commonest site of oral cancer while in our study most common site is tongue.

Squamous cell carcinoma with varying differentiation was the commonest oral malignancy in our study. Most cases of squamous cell carcinoma (107:79.2%) were well differentiated and moderately differentiated [Fig. 1] (26: 12.03%) whereas only 2 (1.48%) were poorly differentiated. This is similar to certain international and local studies.^[10, 13]

Verrucous carcinoma is a specific, well-differentiated and nonmetastasizing variant of squamous cell carcinoma.^[14] It appears as a painless, thick white plaque resembling a cauliflower. The most common sites of oral mucosal involvement include the buccal mucosa, followed by the mandibular alveolar crest, gingiva and tongue. Most patients are elderly males.^[14] In our study there was 5 case of verrucous carcinoma [Fig 2]. Shafer et al^[15] (1972) studied that lesion was common in male and mean age of occurrence was 60-70 years.

Two cases each of basaloid squamous cell carcinoma and rhabdomyosarcoma have been reported in our study. Both cases of Basaloid squamous cell carcinoma were seen in elderly male patient. Two cases of rhabdomyosarcoma diagnosed in adolescent age and were situated on palate and floor of mouth. Considering age and site of lesion our findings are comparable with Franca CM (2006).^[16]

Epithelial precursor lesion (Oral precancerous lesion)

Precancerous lesions are morphologically as well as histologically altered tissues in which chances of malignancy are more as compared to its normal counter part.^[17]

Leukoplakia

Fali S Mehta et al (1969) defined leukoplakia as a white patch of oral mucosa measuring 5mm or more which cannot be scrapped off and which cannot be attributed to any other diagnostic disease.^[18]

In 1975 Charles A. Waldron and William G. Shafer studied 3,256 cases of oral leukoplakia. They found that

leukoplakia occurs chiefly in 5th, 6th and 7th decade of life and it was more common in males.^[19] Buccal mucosa was the most common site followed by labial mucosa, tongue and gingiva.^[20] Smoking alone or smoking in combination with pan or supari and tobacco chewing habits in individuals accounted for the most of the cases of leukoplakia.^[20]

Leukoplakia appeared to be most dangerous precancerous lesion.^[20] Grossly it appears slightly elevated gray or gray white plaque, translucent fissured or wrinkled with sharply demarcated borders.

In later stage it becomes thicker, leathery or Nodular leukoplakia.^[21]

Microscopically it shows a spectrum of changes from hyperkeratosis overlying a thickened acanthotic but orderly mucosal epithelium to lesions with markedly dysplastic changes sometimes merging with carcinoma in situ.

Erythroplakia is defined as red patch that cannot be clinically or pathologically diagnosed as any other condition.^[11] Asymptomatic erythroplakic lesion is the earliest sign of invasive or in situ squamous cell carcinoma.

Microscopically 90% of erythroplakic lesions represent either as severe dysplasia or carcinoma in situ or superficially invasive squamous cell carcinoma.^[21] An intense subepithelial inflammatory reaction with vascular dilatation accounts for red appearance of the lesion.^[11]

In present study 6 cases of carcinoma in situ and 12 cases of dysplasia of varying grades were diagnosed on histopathology. Grossly the lesions were presented as erythroplakia or leukoplakic patch.

Benign tumors

Haemangioma was the most common benign tumor (10 cases), in present study. The tumor is characterized by proliferation of blood vessels. It is most common tumor

of infancy, occurring in 5-10% of 1 year old children. They are common in females than in males. The most common sites of occurrence are lips, tongue, buccal mucosa and palate.^[3]

Other benign lesions that we come across in our study were 2 cases of squamous papilloma and one case each of lipoma, neurofibroma, schwannoma and nevus. Buccal mucosa being the common site for all these tumors. Studies have shown that these lesions are not very common but often occur in the oral cavity.^[22,23]

Tumor like lesions.

Among 32 cases of tumor like lesions maximum number of lesions was located on lower lip and tongue. Mucocele was seen in 16 cases and 10 cases occurred in lip, 3 cases occurred in buccal cavity and 3 cases occurred in tongue. [Fig. 3]

Pyogenic granuloma is a small, pedunculated, haemorrhagic nodule that frequently occurs on the gingiva.

It was first described in 1897 by Poncet and Dor. They called it as Botryomycosis hominis. The name pyogenic granuloma was suggested by Crocker in 1903. It occurs in patients ranging from 14 to 40 years. According to a study conducted by A.P. Angelpoulus gingiva was the most common location, and the lesion shows female preponderance.^[24] There was 11 cases of pyogenic granuloma, gingivae was the most common site.

Epulis fissuratum is tumor like hyperplasia of fibrous connective tissue that develops in association with ill fitting dentures. Bataineh A, AL-Diwari ZN observed peak incidence in 6th decade of life. Males and females are almost equally affected.^[25] In present study we observed 4 cases of epulis fissuratum located on gingivae, with equal sex ratio.

Peripheral giant cell granuloma is exclusively occurs on the gingivae or edentulous alveolar ridge. It is a

pedunculated or sessile lesion arising from deeper tissue. Size of the lesion varies from 0.5 to 1.5 cm. in diameter.^[26] One case of peripheral giant cell granuloma was studied in male patient of 25 years age.

Conclusion:

The oral cavity is one of the most common sites for various tumours and tumour like lesions. Among the malignant lesions, squamous cell carcinoma is single most common malignant lesion of this region. However, the origin and nature of the oral cavity lesions cannot be confirmed by clinical examination alone. Hence, it is must to have a histopathological examination to confirm the histogenesis and malignant potential of the oral lesions.

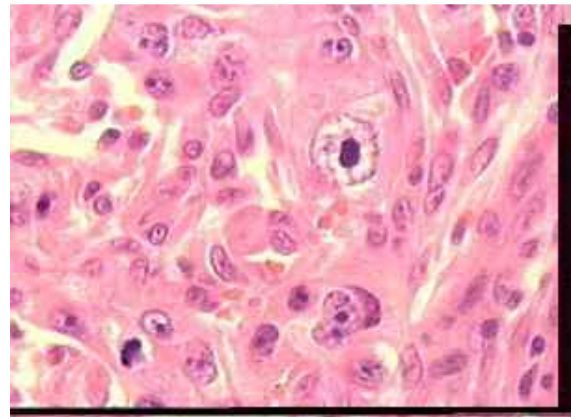


Figure I : Photograph showing moderately-differentiated squamous cell carcinoma with formation of mitotic figures.(H & E Stain, 10X

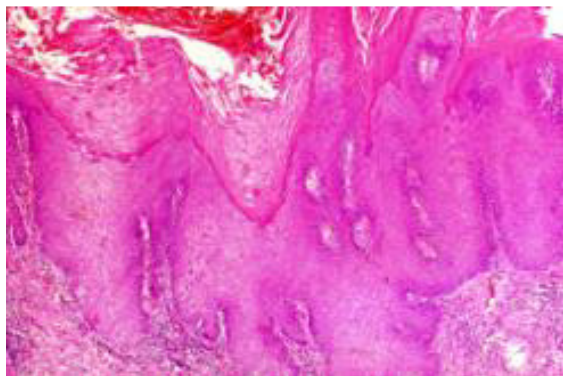


Figure II .Photograph showing Verrucous carcinoma with bulbous rete pegs pushing into underlying stroma. (H & E Stain, 10X)

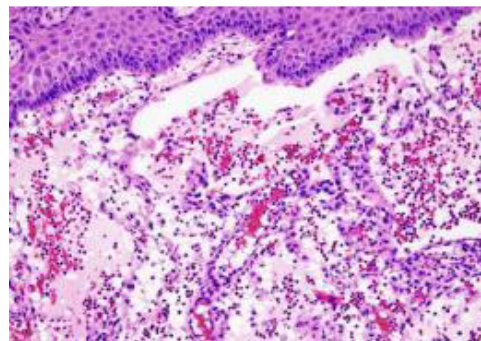


Figure III Photograph showing mucocele with epithelial hyperplasia with underlying area of cyst formation filled with mucin. (H & E Stain, 10X)

Table 1: Distribution of the tumor and tumor like lesions of oral cavity.

Type of lesions	No.of cases	Percentage
Malignant lesions	144	66.87%
Epithelial precursor lesions	18	8.37%
Benign lesions	21	9.76%
Tumor like lesions	32	14.88%
Total	215	100

Table: 2 Age incidence of oral tumor and tumor like lesions in the present study.

Age (years)	Malignant tumors		Epithelial precursor lesion		Benign tumors		Tumor like lesions	
	No	%	No.	%	No	%	No	%
1-10	1	0.69	-	-	3	14.28	8	25
11-20	1	0.69	-	-	6	28.57	13	40.62
21-30	10	6.94	1	5.55	3	14.28	2	6.25
31-40	31	21.57	4	22.22	1	4.76	6	18.75
41-50	41	28.47	5	27.77	5	23.80	-	-
51-60	35	25.00	4	22.22	1	4.76	1	3.12
61-70	20	13.88	4	22.22	2	9.52	1	3.12
71-80	4	2.77	-	-	-	-	-	-
81-90	1	0.69	-	-	-	-	1	3.12
Total	144	100	18	100	21	100	32	100

Table 3: Showing site and sex distribution of oral tumors and tumor like lesion

Site	Malignant tumors				Epithelial precursor lesion				Benign tumors				Tumor like lesion			
	M	F	T	%	M	F	T	%	M	F	T	%	M	F	T	%
Buccal Mucosa	30	16	46	31.94	2	-	2	11.11	5	2	7	33.33	3	1	4	12.5
Oral tongue	32	11	43	29.86	3	3	6	33.33	4	4	8	38.09	3	2	5	15.65
Hard palate	19	2	21	14.98	3	2	5	27.77	1	-	1	4.76	-	-	-	-
Gingiva	5	3	8	5.55	-	-	-	-	-	-	-	-	5	5	10	31.25
Floor of mouth	7	1	8	5.55	1	1	2	11.11	-	-	-	-	-	1	1	3.12
Trigone	2	2	4	2.77	1	-	1	5.55	-	-	-	-	-	-	-	-
Upper lip	1	1	2	1.38	-	-	-	-	2	-	2	9.52	-	-	-	-
Lower lip	10	2	12	8.33	1	1	2	11.11	2	1	3	14.28	6	6	12	37.5
Total	106	38	144	100	11	7	18	100	14	7	21	100	17	15	32	100

References:

1. Mark W. Lingen and Vinay Kumar. Head & Neck (Oral Cavity), A Text Book of Robins and Cotran. Pathologic Basis of Disease. 7th edn. 2004, Elsevier, India. p. 774-782.
2. Nikunj .V.Mehta, Kalpana K. Dave, R.N.Gonsai et al.Histopathological study of oral cavity lesions: A study of 100 cases. Int J Cur ResRev, May 2013/Vol 05 (10).p 110-116.
3. Shafer. Benign and Malignant Tumors of Oral Cavity, A Text book of oral pathology, 4th edn. Harcourt Indian Pvt. Ltd. W.B. Saunder's Co., 1993. p. 86-215.
4. Bushra Ayaz et al. A clinicopathological study of oral cancers. Biomedica ,jun 2011/Vol. 27 .p27-32
5. AD Singh. Challenge of Oral Cancer in India. Indian Journal. of Radiology 1981; 35(3) : 147-155
6. Wahi PN, et al. Head, WHO international reference centre for the histological definition and classification of oral and oropharyngeal tumors. 1971. No. 4, Histological typing of oral & oropharyngeal tumors. P. 15-27.
7. J.J Pindborg J.J, P .A Reichert, C J Smith and Ivander waal In collaboration with L.H Sobin & Pathologists in 9 countries. Histological typing of cancer & precancer of oral mucosa. Second edition 1997.
8. Leon Barnes John W. Eveson Peter Reichart David Sidransky WHO classification of tumors Pathology and Genetics of Head and Neck Tumours IARC Press Lyon, 2005
9. N.N.Khanna ,G.C.Pant,F.M.Tripathi, B.Sanyal ,S.Gupta.Some observations on the etiology of Oral precancerous lesions. Indian Journal of Cancer 1975; 1: 77-82
10. S P Khandekar, P S Bagdey, R R Tiwari. Oral cancer & some epidemiologic factor Hospital Based study. Ind Journal of Community Medicine 2006;31(3):157-158.
11. PK Varshney, N. Agrawal and LM Bariar. Tobacco and Alcohol Consumption in relation to oral cancer. Indian Journal of Otolaryngology and Head and Neck Surg 2003; 55: 25-28.
12. Prakash C Gupta. Tobacco & Youth in the South-East Asian region. Ind Journal of Cancer 2002;5: 29
13. H.Ahluwalia ,S.C Gupta ,Mangal Singh .S.C Gupta Vastla Misra ,P.A Singh ,D.K.Walia .Indian Journal of otolaryngology and Head and Neck Surgery March 2001; 53(1):17-21Cancer
14. Rosai and Ackerman's surgical pathology, 3rd edition,verrucous carcinoma : Chapter 5:246-247
15. W.G.Shafer. Verrucous carcinoma. International Dental Journal 1974;22:451-457.
16. Franca C M, Caran E M M, Elves M D S, Barrato A D, Lopez N N F. Rhabdomyosarcoma of oral tissue- 2 new cases & literature review. Medicine oral Patol cir bucal 2006; 11E(1): 136-140.
17. J.J Pindborg J.J, P .A Reichert, C J Smith and Ivander waal In collaboration with L.H Sobin & Pathologists in 9 countries. Histological typing of cancer & precancer of oral mucosa. Second edition 1997.
18. Fali S.Mehta, J.J.Pindborg, P.C.Gupta D.K.Dattary. Epidemiologic and histologic study of cancer and leukoplakia among 50,519 villagers in India. Cancer 1969;18:831-847
19. Charles A.Waldron and William G.Shafer.Leukoplakia revisited. A clinicopathological study 3,256 oral leukoplakia. Cancer 1975; 36: 1386-1392.
20. Sol Silverman, K..Bhargava, N.J.Mani ,Lowell .W.Smith and A.M.Mallowalla. Malignant transformation and natural history of oral leukoplakia in 57,518 industrial workers of Gujrat,India Cancer 1976; 38: 1795-1976

21. Nivelle Damm, Allen Bouquot .Oral and Maxillofacial pathology .2nd edition.Elsevier 2005 p330-380
22. AL-Khateeb TH. Benign oral masses in a Northern Jordanian population a retrospective study.Open Dent J 2009;3147-53
23. A Furlong-SmithJC, Childers EL. Lipoma of the oral and maxillofacial region:site and subclassification of 125 cases.Oral Surg Oral Med Oral Pathol Oral Radiol Endod 2004;98:441-50
24. Angeopoulos AP.Pyogenic granuloma of the oral cavity: stastical analysis of its clinical features.Journal of .Oral Surg. 1971;29:840-847
25. Bataineh A, AL - Dwairi ZN.A survey of localized lesions of oral tissues:A clinicopathological study.J contemp Dent Pract August 2005 ;(6)3:030-039
26. Ackerman. Oral Cavity and Oral Pharynx. A Text Book of Surgical Pathology. 8th Edn. Mosby St. Louis: 1996. p. 243-245